

# Prevention of Progression of Lipedema With Liposuction Using Tumescent Local Anesthesia; Results of an International Consensus Conference

MATTHIAS SANDHOFER, MD,\* C. WILLIAM HANKE, MD,<sup>†</sup> LOUIS HABBEMA, MD,<sup>‡</sup> MAURIZIO PODDA, MD,<sup>§</sup> STEFAN RAPPRICH, MD,<sup>||</sup> WILFRIED SCHMELLER, MD,<sup>¶</sup> KAREN HERBST, MD,<sup>#</sup> FRIEDRICH ANDERHOBER, PhD,\*\* ULRIKE PILSL, PhD,\*\* GERHARD SATTLER, MD,<sup>§</sup> MARTINA SANDHOFER, MD,\* WERNER MOOSBAUER, MD,<sup>††</sup> SONJA SATTLER, MD,<sup>§</sup> PATRICK SCHAUER, MD,<sup>‡‡</sup> JÖRG FAULHABER, MD,<sup>§§</sup> SABINE MAIER, MD,\* MARTIN BARSCH, MD,\* SONANI MINDT, MD,<sup>|||</sup> AND ANNE B. HALK, MD<sup>¶¶</sup>

**BACKGROUND** Lipedema is a chronic, progressive disorder of subcutaneous adipose tissue that usually affects the lower extremities of women. Also known as “two-body syndrome,” the fat accumulations in lipedema are unsightly and painful. The disorder is well-known in Europe but is largely unrecognized and underdiagnosed in the United States.

**OBJECTIVE** To hold the First International Consensus Conference on Lipedema with the purpose of reviewing current European guidelines and the literature regarding the long-term benefits that have been reported to occur after lymph-sparing liposuction for lipedema using tumescent local anesthesia.

**METHODS** International experts on liposuction for lipedema were convened as part of the First International Congress on Lipedema in Vienna, Austria, June 9 to 10, 2017.

**RESULTS** Multiple studies from Germany have reported long-term benefits for as long as 8 years after liposuction for lipedema using tumescent local anesthesia.

**CONCLUSION** Lymph-sparing liposuction using tumescent local anesthesia is currently the only effective treatment for lipedema.

*An international consensus conference on lipedema was conducted in conjunction with the First International Congress on Lipedema. The Congress was sponsored by the Austrian Academy of Cosmetic Surgery and Aesthetic Medicine (AACMS) and the International Society for Dermatologic Surgery (ISDS) and was held in Vienna, Austria, June 9 to 10, 2017. The consensus conference participants included the following physicians: M. Sandhofer, L. Habbema, G. Sattler, S. Rapprich, W. Schmeller, F. Anderhuber, M. Podda, K. Herbst, W. Moosbauer, M. Sandhofer, U. Pils, S. Sattler, P. Schauer, J. Faulhaber, S. Maier, S. Mindt, A.B. Halk, M. Barsch, and C.W. Hanke.*

Lipedema is believed to affect 11% to 39% of the female Caucasian population worldwide, but exact figures from large studies are not available.<sup>1,2</sup> As many as 16 million women in the United States may be affected with the disorder.<sup>3</sup> This potentially aggressive

disease is characterized by progressive enlargement of the lower body while the upper body remains relatively normal.<sup>4</sup> The disease eventuates in deformity, disability, and reduced quality of life. Current guidelines for treatment of lipedema exist

\*Linz, Austria; <sup>†</sup>Laser and Skin Surgery Center of Indiana, Indianapolis, Indiana; <sup>‡</sup>Medisch Centrum't Gooi Prinsengracht, Amsterdam, the Netherlands; <sup>§</sup>Darmstadt, Germany; <sup>||</sup>Bad Soden, Germany; <sup>¶</sup>Hanse-Klinik, Luebeck, Germany; <sup>#</sup>Tucson, Arizona; \*\*Institute of Macroscopic and Clinical Anatomy, Graz, Austria; <sup>††</sup>Kepler Universitätsklinikum GmbH, Linz, Austria; <sup>‡‡</sup>Passau, Germany; <sup>§§</sup>Schwäbisch Gmünd, Germany; <sup>|||</sup>Institute for Clinical Chemistry, University Hospital Mannheim, Mannheim, Germany; <sup>¶¶</sup>Amsterdam, the Netherlands

only in Germany, Austria, and the Netherlands.<sup>5-7</sup> The clinical presentation of lipedema has been reviewed by European dermatologists.<sup>4</sup> The purpose of the consensus conference was to review the current guidelines and make recommendations especially with respect to long-term benefits that may occur after treatment of lipedema with liposuction using tumescent local anesthesia. Expert opinion is important because of limited evidence-based data on lipedema. The tables included in the article are consensus-based and do not mandate obligatory action.

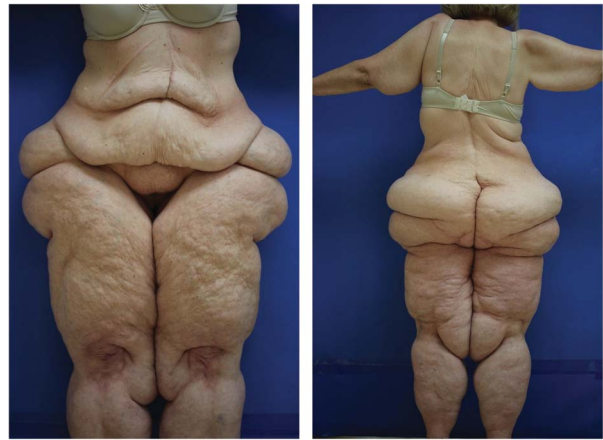**Introduction**

Lipedema, also called lipoedema in Europe, is a chronic progressive disorder of subcutaneous adipose tissue usually affecting the lower extremities of women.<sup>4</sup> The fat accumulations are unsightly and painful. First described by Allen and Hines<sup>8</sup> in 1940, the disease is infrequently diagnosed in the United States, although it is well-known in Europe. Lipedema, also called “two-body syndrome,” is relatively easy to diagnose by comparing the upper and lower body during a physical examination (Figure 1). The circumference of the legs is proportionately larger than the trunk. The feet are not affected (as in lymphedema), and the fat accumulations stop abruptly in the ankle region, below the knee, above the outer thigh, above the hips/buttocks, and below the elbow. Bruising of the skin in the involved areas occurs after minimal trauma (Table 1).

Lipedema leads to multiple problems including decreased mobility and activity, secondary obesity, reduced general health, difficulty finding properly fitting clothing, and feelings of embarrassment. When obesity develops in conjunction with lipedema, the trunk and upper body will also demonstrate enlargement.

**Comorbid Conditions With Lipedema**

Diabetes and hypertension are uncommon in lipedema patients. Only one of 51 lipedema patients in Herbst’s series had Type 2 diabetes.<sup>3</sup> Three of 500

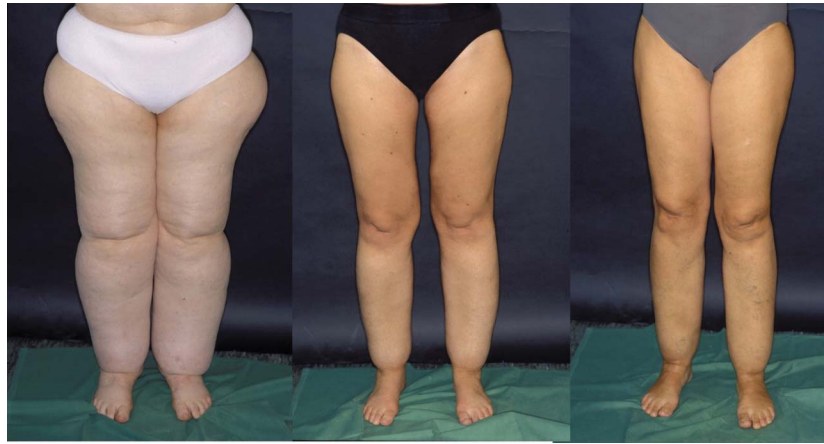

**Figure 1.** (Front and back): A 50-year-old woman exhibits the typical clinical features of Stage III lipedema or “two-body syndrome”. The area above the waist is normal except for excess subcutaneous fat on the arms. The areas below the waist demonstrate severe deformity.

lipedema patients in Sandhofer’s series had diabetes.<sup>9</sup> These observations suggest that lipedema fat is not insulin-resistant and may protect patients from developing diabetes. Herbst and coworkers<sup>3</sup> reported an increase in palpitations, numbness, urination, and shortness of breath in patients with lipedema stage III. However, the gynoid fat distribution (i.e., thighs, buttocks, and hips) in lipedema may provide reduced cardiac risk for patients. Thyroid stimulating hormone (TSH) should be monitored yearly in patients who have lipedema and obesity. The prevalence of hypothyroidism in

**TABLE 1. Lipedema is a Disease**

Uncontrolled localized fat deposition involving the lower extremities (usually legs and thighs)
Symmetric increase in adipose tissue (“two-body syndrome”)
Onset at puberty, pregnancy, and menopause
Women-progressive with age (in most cases)
Tired “heavy” legs
Pain to touch or pressure may be mild or severe
Easy bruising
Hands and feet usually not affected (unlike lymphedema)
Cuffs or bulges develop around joints (e.g., ankles, knees, elbows, and wrists)
Negative Stemmer’s sign
Palpable spheroids in lipedema fat
Reduced ambulation, decreased social activity



**Figure 2.** A mother has Stage III lipedema and her 2 daughters have Stage II lipedema. The genetic predisposition is clear. (Reprinted with permission Johns Wiley and Sons, publisher) Rapprich S, Dingler A, Podda M. Liposuction is an effective treatment for lipedema results of a study with 25 patients. *J Dtsch Dermatol Ges* 2011;9(1):33–40.

lipedema may be as high as 27%.<sup>3</sup> In a consecutive series of 50 patients with lipedema, Herbst found hypermobile joints is 50%.<sup>3</sup> Herbst has reported that 50% of lipedema patients have hypermobile joints, suggesting an association with Ehlers Danlos syndrome hypermobility type.<sup>3</sup>

### Etiology

The cause of lipedema is unknown. A family history of lipedema has been reported in up to 60% of cases (Figure 2). Lipedema commonly begins at puberty but may also become apparent with pregnancy or menopause. Although predominantly in women, lipedema has been reported to occur occasionally in hypogonadal men.<sup>3</sup> Hypertrophy and hyperplasia of adipocytes occurs in the involved areas. Capillary permeability and fragility is increased causing easy bruising. Long-term strain on lymphatic vessels results in lymphatic stasis and degenerative changes in vessel walls. Ultimately, fibrosis of subcutaneous fat occurs as increasing surface deformities develop.

**TABLE 2. Classification of Lipedema by Anatomical Site (Schrader) (German S1 Guidelines)**

Type I	Buttocks and saddlebags
Type II	Thigh (to the knee)
Type III	Legs (to malleoli)
Type IV	Arms
Type V	Calves only

### Clinical Features of Lipedema

Clinical features are listed in Tables 2–4. The “cuff sign” is often present below the knee, above the ankles, above the elbow, and above the waist (Figure 3). The patella can disappear into the surrounding fat, making ambulation, and bending of the knee difficult (Figure 4). Forced spread of the legs due to painful fat deposits often causes mechanical problems and decreased mobility.

The “bottleneck” fat pad or “subpatellar fat pad” on the anterior surface of the leg just below the knee is believed to be diagnostic of lipedema (Figure 5). It is speculated, that the deformity is caused by subcutaneous lymphatic stasis and irregular subcutaneous fat accumulation. Herbst and others have observed that lipedema fat contains small 5- to 10-mm firm palpable bean-like structures called spheroids. Lifestyle-induced fat

**TABLE 3. Clinical Stages of Lipedema (Stroessenreuther) (German S1 Guidelines)**

Stage I	Smooth and even skin surface; enlarged subcutaneous fat compartment
Stage II	Skin surface wavy with some nodular elevations and indentations
Stage III	Large nodules and deforming hanging fat flaps, esp. on thighs and knees
Stage IV	Lipolymphedema occurs due to dysfunctional lymphatics

**TABLE 4. Differential Clinical Signs in Lipedema, Lipohypertrophy, Obesity, and Lymphedema (S1 Guideline 037/012: Lipedema Last Updated 10/2015 Published by: AWMF Online. The Scientific Medicine Portal. doi:10.1111/ddg.13036)**

	<i>Lipedema</i>	<i>Lipohypertrophy</i>	<i>Obesity</i>	<i>Lymphedema</i>
Increased fat tissue	+++	+++	+++	(+)
Disproportion	+++	+++	(+)	+
Edema	(+)	–	(+)	+++
Pain on pressure	+++	–	–	–
Easy bruising	+++	(+)	–	–

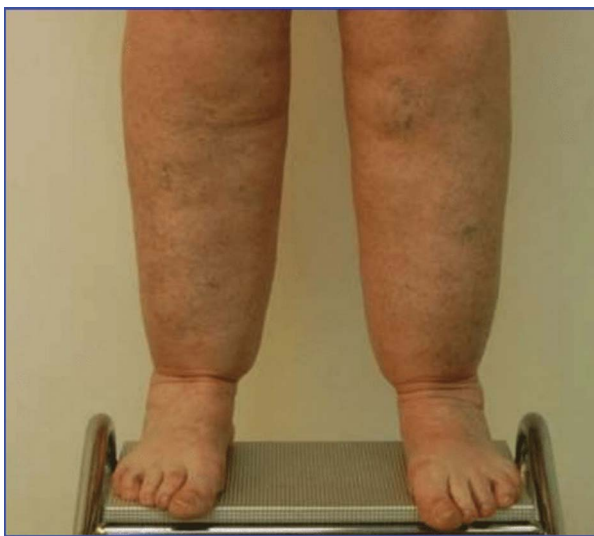+ to +++, present; (+), possible; –, not present.

does not contain spheroids.<sup>3</sup> The numbers of spheroids increase as patients progress by lipedema stage. All patients with Stage III lipedema have palpable spheroids in the flanks, thighs, buttocks, medial knee, and posterior leg.<sup>3</sup> Lipomas are not present in large numbers in patients with lipedema.

Associated findings in lipedema can include obesity, venous disease, joint pain, and hypermobile joints.

Several classifications and staging systems for lipedema have been proposed (Tables 2–4 and Figure 6).

Without treatment, lipedema will progress through the various stages (Figure 7).

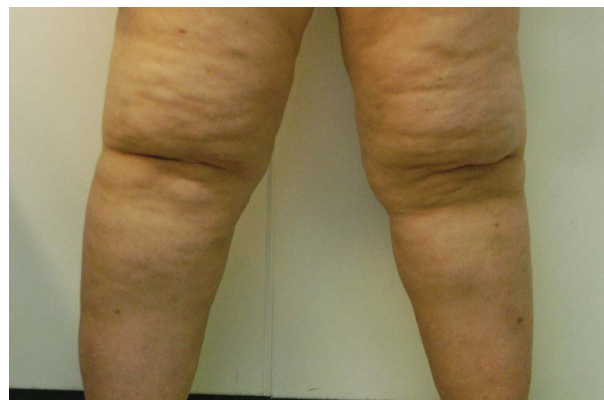

**Figure 3.** “Cuff sign” above the ankles with sparing of feet is common in lipedema patients.

### **Treatment of Lipedema**

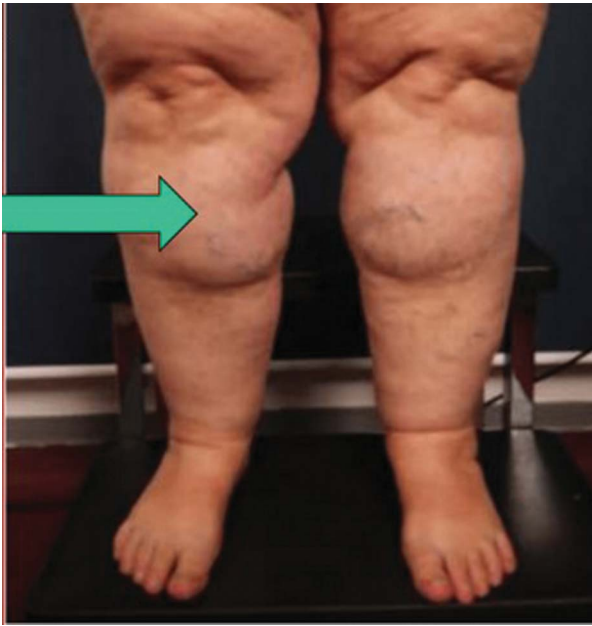Treatment of lipedema includes both nonsurgical and surgical methods. The goal of treatment is to improve the signs and symptoms of increasing leg volume, which include pain, swelling, limb disproportion, maceration, and to prevent infection, erysipelas, lymphedema, and gait problems (Tables 5–7).

Manual lymphatic drainage (MLD), intermittent pneumatic compression, compression stockings, exercise, and skin care are often used to control pain and symptoms. Recent studies have shown that there is little or no edema in lipedema.<sup>10,11</sup> Therefore, treatment with MLD has no significant therapeutic effect on lipedema except perhaps making the patient feel better because of the “hands-on” nature of MLD. Diet is often used to prevent or treat obesity when it is associated with lipedema. It is



**Figure 4.** A patient with lipedema demonstrates hooding of the patella and the subpatellar fat pad on the anterior upper leg.

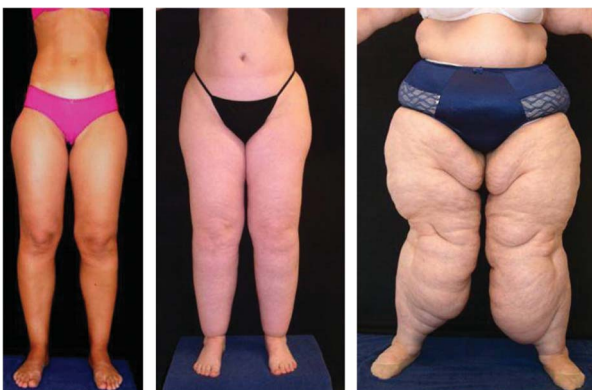



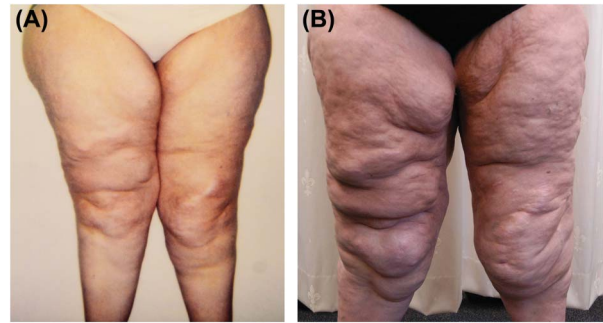
**Figure 5.** Subpatellar (“bottleneck”) fat pad below the knee is common in lipedema patients.

essential for lipedema patients to avoid weight gain. “yo-yo” dieting and obesity have been shown to exacerbate lipedema.<sup>10,11</sup>

Surgical treatment involves delicate, atraumatic lymph-sparing liposuction using tumescent local anesthesia. The treatment has been proven to be safe and effective for cosmetic indications and lipedema.<sup>12–19</sup> Examination of adipose tissue using lymphoscintigraphy and immunohistochemistry has demonstrated no significant damage to lymphatic vessels from liposuction using tumescent local anesthesia compared with traditional lipo-



**Figure 6.** Patients demonstrating lipedema (Stage I, II, III).



**Figure 7.** (A and B) Lipedema Progression over 13 years without treatment.

suction techniques using general anesthesia. Liposuction techniques using radio frequency, ultrasound, or laser are not useful for lipedema patients because of possible damage to lymphatic vessels.

The frequency and necessity of conservative non-surgical maintenance treatment were shown to be eliminated or reduced after liposuction using tumescent local anesthesia. The reduction in adipose deformities on the legs and thighs reduces skin damage and facilitates improvement in mobility and gait (Figures 8 and 9).

**Treatment Planning in Liposuction for Lipedema**

Some members of the Consensus group felt that the most painful areas of lipedema should be treated first, although patient preferences must also be

**TABLE 5. Treatment Goals for Lipedema Patients Treated With Liposuction Using Tumescent Local Anesthesia**

Primary Goals	Secondary Goals
↑ Mobility and ↑ improvement in gait	Improved body contour
↓ Excess subcutaneous fatty tissue and bulkiness	↓ Weakness and fatigue
↓ Pain (spontaneous, continuous, intermittent, and painful to touch)	Aesthetic improvement
Improved quality of life	↓ Edema
↓ Bruising	↓ Skin irritation, breakdown
	↑ Self-esteem

**TABLE 6. Lidocaine and/or Prilocaine Protocols for Tumescent Local Anesthesia**

	<i>Klein</i> <sup>12</sup>	<i>Sattler, 1994</i>	<i>Hamburger, 1998</i>	<i>Habbema</i> <sup>19</sup>
NaCl 0.9% mL	1,000	1,000	1,000	1,000
Lidocaine, mg	1,000	—	200	400
Prilocaine, mg	—	400	200	—
Epinephrine, mg	1	1	1	0.8
NaHCO <sub>3</sub> 8.4% mL	12.5	6	6	10
Triamcinolone 10 mg/mL	1 (0)	1	1	—
I.V. Sedation/Pain	No/rare	Yes	Yes/no	No

taken into consideration. In general, liposuction sessions should be begun proximally on the thigh with subsequent treatment sessions on the lower legs.

Maximum total lidocaine dose is restricted to 55 mg/kg in young women and 45 mg/kg in women over 60 years. Liposuction in lipedema patients is generally more labor-intensive in all aspects of the procedure compared with liposuction in aesthetic patients because of the large amounts of fatty tissue that are often removed.

The venous system should be assessed preoperatively in Stage III to IV lipedema patients, but not Stage I to II patients unless indicated by physical examination and symptoms (Table 8). Some experts recommend that vein surgery be completed 2 months before liposuction to reduce phlebolymphe­dema and bleeding complications.

One of the hallmarks of liposuction using tumescent local anesthesia is the “state of tumescence.” The state of tumescence is characterized by white blanching of the skin and a firm “watermelon” like surface that persists for more than 30 minutes. This persistent firmness indicates that the proper amount of tumescent local anesthesia has been delivered to the target tissue.

Both extremities should be treated during the same treatment session to maximize symmetry and improvement. Two treatment algorithms are outlined in Table 9. Treatment plans for lipedema stages I to III are listed in Tables 10–12.

**Postoperative Course**

Lipedema patients treated with liposuction using tumescent local anesthesia (TLA) may drain lymph fluid for several weeks following the procedure. Swelling of the treated area may last for 4 weeks or more.

Low-dose heparin is given by some European liposuction surgeons as prophylaxis to prevent deep vein thromboses.

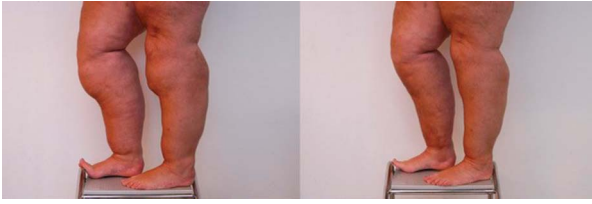Postoperative antibiotics are given for 1 to 2 weeks postoperative.

Compression stockings are worn for 2 to 4 weeks postoperatively to prevent pools of lymph from forming in suctioned areas. After the first 4 weeks, patients may prefer to wear compression stockings daily for comfort and support.

Manual lymphatic drainage can be given for as long as 4 to 5 weeks postoperative. Acoustic wave therapy may be given for 5 to 10 weeks.

**TABLE 7. Technical Differences With Liposuction in Lipedema and Lipohypertrophy**

<i>Lipedema</i>	<i>Lipohypertrophy</i>
Extensive areas	Localized areas
Large volume fat removal	Limited fat removal
Circumferential treatment	Localized removal
Multiple sessions	One or more limited sessions
Longer downtime	Limited downtime



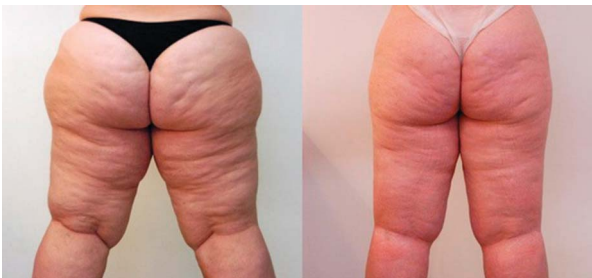**Figure 8.** A 42-year-old woman demonstrates typical lipedema with enlargement of both legs. The girth of both legs has been reduced after multiple liposuction procedures using tumescent local anesthesia. Total volume of supranatant fat removed was 5.5 L.

Low-impact active movements may begin when all liposuction incisions are closed or healed. These activities can include walking, aqua-gymnastics, swimming, and gymnastics.

### **Long-Term Results in Lipedema Treated With Liposuction Using Tumescent Local Anesthesia**

Schmeller and co workers<sup>20–22</sup> and Rapprich and co workers<sup>23–25</sup> have reported dramatic long-term benefits in lipedema patients treated with liposuction using tumescent local anesthesia.

In 2016, Baumgartner and coworkers<sup>22</sup> reported 8-year follow-up on 85 lipedema patients treated with liposuction using tumescent local anesthesia. The same group of patients had been evaluated 4 years after liposuction.<sup>20</sup> The improvement is spontaneous pain, pressure sensitivity, bruising, edema, and mobility that occurred at 4 years postoperative was sustained at 8 years. Improvement in cosmetic appearance, quality of life, and overall impairment was also sustained at 8 years. Patients experienced a reduced need for conser-



**Figure 9.** A 34-year-old woman demonstrates typical lipedema with enlargement of the thighs and buttocks. A total of 9.8 L supranatant fat removed during several liposuction procedures.

### **TABLE 8. Technical Aspects of Liposuction for Lipedema Using Tumescent Local Anesthesia**

2–6 treatment sessions may be required
The liposuction technique should cause the least possible trauma to blood vessels, nerves, and lymphatics
Bilateral areas should be treated during the same treatment session to minimize asymmetry
Patients will require long-term follow-up
The dripping of lymph fluid may persist for 2–4 days postoperatively
The necessity of treatment for varicose veins is determined on an individual basis. Small varicosities may require no treatment, whereas large varicosities are often treated in advance of liposuction.

vative therapy at 4 and 8 years. One-third of patients were free of symptoms entirely after liposuction.

The authors hypothesized that the accumulation of subcutaneous fatty tissue is the central factor in the pathogenesis of lipedema.<sup>22</sup> Pain, easy bruising, and edema are secondary factors that are diminished or resolved after liposuction. The authors indicated that liposuction should be considered when symptoms progress during conservative therapy (Tables 13 and 14).

Rapprich and coworkers<sup>25</sup> assessed 85 lipedema patients who underwent liposuction using tumescent local anesthesia at 6 months after treatment. The mean number of treatment sessions was 2.61/patient. After liposuction, lipedema patients experienced improvement in spontaneous leg pain, tenderness, bruising, swelling, ambulation, and quality of life.

### **Future/Research**

Stem cells in lipedema may ultimately prove to be different from those in normal fat. Much higher yields of stem cells have been reported in the stromal vascular fraction of lipedema fat compared with normal fat cells.<sup>26</sup> These cells may ultimately become a tissue regeneration option in lipedema patients. Hematoxylin and eosin staining reveals crown-like structures in lipedema fat cells. It is not clear if the crown-like structures are a primary cause for the growth of a

**TABLE 9. Two Treatment Algorithms for Lipedema Patients Treated With Liposuction Using Tumescent Local Anesthesia (the Minimum Interval Between Treatment Sessions is Usually 4 Weeks or More)**

First session	Inner thighs and knees	▶ <u>May be reversed if desired</u>
Second session	Outer thighs and hips	
Third session	Lower legs (circumferential is sometimes done)	
First session	Outer thighs and hips	
Second session	Inner thighs and knees	
Third session	Ant upper leg and upper arms (if necessary)	
Fourth session	Hips and sacral area (if necessary)	
Fifth session	Buttocks (if necessary)	

**TABLE 10. Liposuction Using Tumescent Local Anesthesia in Stage I Lipedema Patients (Sattler 2017)**

1–3 treatment sessions may be required
Small varicose veins do not require treatment before liposuction
Most painful areas should be treated first, although there may be exceptions to this rule
Long-term follow-up is necessary

**TABLE 13. Improvements in Lipedema Symptoms/Complaints After Liposuction**

<i>Less Mechanical Problems</i>	<i>Reduced Complaints</i>
↓ friction dermatitis	↓ pain
↓ forced leg spread	↓ fatigue
↑ mobility	↓ edema and ↓ bruising
↑ fitting of clothing	↑ self-esteem
↑ fitting of boots	↓ joint pain

**TABLE 11. Liposuction Using Tumescent Local Anesthesia in Stage II Lipedema Patients (Sattler 2017)**

2–4 treatment sessions may be required
Large varicose veins may need treatment before liposuction
Most painful areas should be treated first, although there may be exceptions to this rule
Long-term follow-up is necessary

**TABLE 14. Total Lipedema Treatment Plan**

Patient education
Conservative therapy
Diet and exercise (to prevent secondary obesity)
Lymphatic drainage and compression therapy
Psychotherapy/counseling
Precision, delicate lymph-sparing liposuction under tumescent local anesthesia

**TABLE 12. Liposuction Using Tumescent Local Anesthesia in Stage III Lipedema Patients (Sattler 2017)**

3–6 treatment sessions may be required
Large varicose veins may need treatment before liposuction
3–6 areas are likely to be affected
Most painful areas should be treated first, although there may be exceptions to this rule
Long-term follow-up is necessary

Ehlers Danlos syndrome requires further investigation.<sup>3</sup>

Lymph-sparing liposuction using tumescent local anesthesia is the only effective treatment for patients with lipedema.

**References**

1. Beninson J, Edelglass JW. Lipedema—the non-lymphatic masquerader. *Angiology* 1984;35:506–10.
2. Foeldi M, Foeldi E. “Lipedema” in *Foeldi’s Textbook of Lymphology*. Munich, Germany: Elsevier; 2006; pp. 417–427.
3. Herbst KL, Mirkovskaya L, Bharhagova A, Chava Y, et al. Lipedema, fat signs and symptoms of illness increase with advancing age. *Arch Med* 2015;7:1–8.

different lipedema-type subset of fat cells or a secondary effect due to an enlarged hypodermis. Herbst’s suggestion of an association between lipedema and



4. Langendoen SI, Habbema L, Nijsten TEC, Neumann HAM. Lipedema from clinical presentation to therapy: a review of the literature. *Br J Dermatol* 2009;161:980–6.
5. Wienert V, Walderman F, Zabel M, Rabe E, et al. Guidelines of the German society of phlebology. *Phlebologie* 2009;38:164–7.
6. Damstra RJ, Habbema L, Hendrickx C, Feenstra C, et al. *Lipedema Guidelines (g) in the Netherlands*. Utrecht, the Netherlands: Dutch Society for Dermatology and Venereology; 2014. Available from: <https://www.lymfoedeem.nl/files/publicatie-r-damstra-april-2017-2.pdf>. Accessed July 8, 2019.
7. Reich-Schupke S, Schmeller W, Brauer WJ, Cornely ME, et al. *S1 guidelines: lipedema*. *J Dtsch Dermatol Ges* 2017;15:758–67.
8. Allen EV, Hines EAJ. Lipedema of the legs: a syndrome characterized by fat legs and orthostatic edema. *Proc Staff Meet Mayo Clin* 1940;15:184–7.
9. Sandhofer M, Schauer P, Sandhofer M, Anderhuber F. Lipedema: Anatomic study, diagnosis and perioperative environment. *J Aesthet Chir* 2017;10:61–70.
10. Bertsch T, Erbacher G. Lipoedema-myths and facts Part 1. *Phlebologie* 2018;2:84–92.
11. Bertsch T, Erbacher G. Lipoedema-myths and facts Part 2. *Phlebologie* 2018;3:120–6.
12. Klein JA. The tumescent technique for Lipo-suction surgery. *Am J Cos Surg* 1987;4:263–7.
13. Klein JA, Jeske DR. Estimated maximal safe dosages of tumescent lidocaine. *Anesth Analg* 2016;122:1350–9.
14. Hanke CW, Bernstein G, Bullock S. Safety of tumescent liposuction in 15,336 patients. National survey results. *Dermatol Surg* 1995;21:459–62.
15. Hanke CW, Cox SE, Kuznets N, Coleman WP III. Tumescent liposuction report performance measurement initiative: national survey results. *Dermatol Surg* 2004;30:967–77; discussion 978.
16. Housman TS, Lawrence N, Mellen BG, George MN, et al. The safety of liposuction: results of a national survey. *Dermatol Surg* 2002;28:971–8.
17. Boeni R. Safety of tumescent liposuction under local anesthesia in a series of 4,380 patients. *Dermatology* 2011;222:278–81.
18. Habbema L. Safety of liposuction using exclusively tumescent local anesthesia in 3,240 consecutive cases. *Dermatol Surg* 2009;35:1728–35.
19. Habbema L. Efficacy of tumescent local anesthesia with variable lidocaine concentration in 3430 consecutive cases of liposuction. *J Am Acad Dermatol* 2010;62:988–94.
20. Schmeller W, Hueppe M, Meier-Vollrath. Tumescent liposuction in lipedema yields good long-term results. *Br J Dermatol* 2012;166:161–8.
21. Schmeller W, Baumgartner A, Frambach Y. *Tumescent Liposuction in Lipoedema in Liposuction: Principles and Practice*. In: Schiffman MA, DiGiuseppe A, editors. Berlin, Germany: Springer-Verlag; 2016.
22. Baumgartner A, Hueppe M, Schmeller W. Long-term benefit of liposuction in patients with lipoedema: a follow-up study after an average of 4 and 8 years. *Br J Dermatol* 2016;174:1061–7.
23. Rapprich S, Koller J, Sattler G, Wörle B, et al. Liposuction—a surgical procedure in dermatology. *J Dtsch Dermatol Ges* 2012;10:111–3.
24. Rapprich S, Dingler A, Podda M. Liposuction is an effective treatment for lipedema—results of a study with 25 patients. *J Dtsch Dermatol Ges* 2011;9:33–40.
25. Rapprich S, Baum S, Kaak I, Kottmann T, et al. Treatment of lipoedema using liposuction. *Phlebologie* 2015;3:1–13.
26. Priglinger E, Wurzer C, Steffenhagen C, Maier J, et al. The adipose tissue- derived stromal vascular fraction cells from lipedema patients: are they different? *Cytotherapy* 2017;19:849–60.

---

Address correspondence and reprint requests to: C. William Hanke, Laser and Skin Surgery Center of Indiana, 8925 N. Meridian Street #200, Indianapolis, IN 46260, or e-mail: [cwmhanke@thelassi.com](mailto:cwmhanke@thelassi.com)