

Lipedema: A Relatively Common Disease with Extremely Common Misconceptions

Donald W. Buck II, MD*
Karen L. Herbst, MD, PhD†

Lipedema, or adiposis dolorosa, is a common adipose tissue disorder that is believed to affect nearly 11% of adult women worldwide. It is characterized most commonly by disproportionate adipocyte hypertrophy of the lower extremities, significant tenderness to palpation, and a failure to respond to extreme weight loss modalities. Women with lipedema report a rapid growth of the lipedema subcutaneous adipose tissue in the setting of stress, surgery, and/or hormonal changes. Women with later stages of lipedema have a classic “column leg” appearance, with masses of nodular fat, easy bruising, and pain. Despite this relatively common disease, there are few physicians who are aware of it. As a result, patients are often misdiagnosed with lifestyle-induced obesity, and/or lymphedema, and subjected to unnecessary medical interventions and fat-shaming. Diagnosis is largely clinical and based on criteria initially established in 1951. Treatment of lipedema is effective and includes lymphatic support, such as complete decongestive therapy, and specialized suction lipectomy to spare injury to lymphatic channels and remove the diseased lipedema fat. With an incidence that may affect nearly 1 in 9 adult women, it is important to generate appropriate awareness, conduct additional research, and identify better diagnostic and treatment modalities for lipedema so these women can obtain the care that they need and deserve. (*Plast Reconstr Surg Glob Open* 2016;4:e1043; doi: 10.1097/GOX.0000000000001043; Published online 28 September 2016.)

Despite its description in 1940 by Allen and Hines,¹ little is understood about the adipose tissue disorder, lipedema. Lipedema is described as “adiposis dolorosa,” or painful fat, and is related to the more extreme adipose tissue disorder, Dercum’s disease. If estimates are correct, lipedema may affect millions of women in the United States alone, with an estimated incidence of 1 in 9 adult women.² Little is known about the etiology of this condition, and few physicians recognize the constellation of signs and symptoms to properly diagnose it. As such, the women with lipedema are left to suffer the gauntlet of medical mystery, and the judgment of family, friends, physicians, and strangers alike.

Far too often, the women who suffer from lipedema are told that their leg growth and swelling is a result of

their inability to control their diet or of their sedentary lifestyles. As if to suggest acceptance, they are often told that the women in their families just “have big legs.” As their disease progresses and they return to their physicians with increasing leg swelling and weight, patients with lipedema are frequently questioned about their compliance with diet and exercise recommendations. As a result of a fixation on their increasing weight and growing body habitus, coupled with the “fat-shaming,” which runs rampant in society today, women with lipedema frequently suffer from significant psychosocial distress, including anxiety, depression, eating disorders, and isolation.³

One of the most common misconceptions about patients with lipedema is that they suffer, instead, from lifestyle- or diet-induced obesity. Although some patients with lipedema may also have obesity and although the obesity may influence the lipedema subcutaneous adipose tissue, lipedema is a mutually exclusive diagnosis and should be considered as such. Unlike obesity, the adipocyte hypertrophy and swelling associated with lipedema are resistant to change with diet and exercise or bariatric surgery and caloric restriction.³ In fact, some patients may experience a growth in their lipedema fat in the setting of these stressors. Most patients with lipedema will have involvement of

From the *Division of Plastic and Reconstructive Surgery, Washington University School of Medicine, St. Louis, Mo.; and †Department of Medicine, University of Arizona, Banner University Medical Center, Tucson, Ariz.

Received for publication June 28, 2016; accepted August 3, 2016.

Copyright © 2016 The Authors. Published by Wolters Kluwer Health, Inc. on behalf of The American Society of Plastic Surgeons. All rights reserved. This is an open-access article distributed under the terms of the Creative Commons Attribution-Non Commercial-No Derivatives License 4.0 (CCBY-NC-ND), where it is permissible to download and share the work provided it is properly cited. The work cannot be changed in any way or used commercially.

DOI: 10.1097/GOX.0000000000001043

Disclosures: Dr. Buck is a paid consultant for the Musculoskeletal Transplant Foundation (MTF), SteadMed Medical Inc., and Tactile Medical. The other author has no financial interest to declare in relation to the content of this article. The Article Processing Charge was paid for by the authors.

Table 1. Comparison of Findings in Lipedema, Lymphedema, and Lifestyle-induced Obesity

	Lipedema	Lymphedema	Lifestyle-induced Obesity
Sex	Women	Women and men	Women and men
Adiposity	Bilateral extremities Symmetric	Unilateral or bilateral extremities Asymmetric	Whole body, proportionate Symmetric
Edema	Nonpitting Minimal change with elevation; minimal change with compression	Pitting Reduced by elevation; reduced with compression	None No change with elevation or compression
Tissue turgor	Soft	Firm	Soft
Pain	Tender to palpation	Usually nontender	None
Infection	Rare	Common	Rare

the extremities exclusively.⁴ This significant discrepancy in adiposity of the extremities compared with the trunk is often a hallmark of lipedema, whereas the adiposity associated with lifestyle-induced obesity is generally global and proportionate. Likewise, despite an elevated body mass index, the incidence of diabetes is relatively low among women with lipedema (Table 1).^{3,5}

Another common misconception of patients with lipedema is that they are actually suffering only from lymphedema. In fact, studies by Földi and Földi suggest that up to 15% to 17% of women being treated for lymphedema have lipedema as well.^{2,6,7} Although lymphatic dysfunction is a common finding in late stages of lipedema, there are many distinguishing characteristics that differentiate lipedema from lymphedema (Table 1). One of the classic findings with lipedema is the relative sparing of the feet and hands. As if wearing a rubber band bracelet or anklet, the “swelling” and enlargement of the extremities end abruptly at the wrist and ankles. Unlike patients with lymphedema, women with lipedema can often wear regular tennis shoes and can pinch the skin on the dorsum of their feet and hands without difficulty (“negative” Kaposi–Stemmer sign).⁴

Although there is relatively little known about the molecular phenomenon that leads to this disease, there are clear clinical signs and symptoms associated with lipedema that make clinical diagnosis possible. The diagnostic criteria for lipedema were first described in 1951 by Wold et al⁴ and have been modified in recent years by Herbst³ (Table 2). Lipedema almost exclusively occurs in women, with the onset typically by the third decade of life. The classic appearance of lipedema includes bilateral and

symmetrical involvement of the lower extremities, with sparing of the feet (Fig. 1). Patients will typically describe themselves as a body with disproportionate halves. The lipedema subcutaneous adipose tissue is nonpitting and stops at the ankle. The adiposity is granular to palpation, with a “sand grain” texture, but can also be nodular with a “beans in a bag” feel and is significantly tender to pressure and touch.⁸ Patients with lipedema bruise easily and may have telangiectasias corresponding to fragile subdermal capillaries.³

Lipedema consists of 5 major types, with types 1 to 3 being the most common (Table 3). It is important to note that individual patients can present with a mixture of types. Like many diseases, lipedema has a tendency to progress over time such that disease severity can be described in stages. There are currently 4 reported stages of lipedema: stage 1 involves an even skin surface with an enlarged hypodermis, stage 2 involves an uneven skin pattern with the development of a nodular or mass-like appearance of subcutaneous fat, lipomas, and/or angioli-pomas, stage 3 involves large growths of nodular fat causing severe contour deformity of the thighs and around the knee, and stage 4 involves the presence of lipolymphedema.^{2,3}

Because of their similarities, and even though lipedema is believed to be more common, it can be considered a disease along the spectrum of rare adipose disorders, or adipose tissue disorders, which includes familial multiple lipomatosis, Madelung’s disease, and Dercum’s disease.³ At present, little is known about whether each of these diseases represents a truly unique disorder or rather a variation of a common underlying molecular phenomenon of adipocyte growth and hyperplasia. From a clinical perspective, lipedema can be distinguished from familial multiple lipomatosis, Madelung’s disease, and Dercum’s disease because of the hallmark shape of the lipedema subcutaneous adipose tissue; relative sparing of the face, neck, and trunk; and fatty tumors in the subcutaneous adipose tissue that do not dominate the presentation as in the other rare adipose disorders.^{3,9}

PATHOLOGY OF LIPEDEMA

For a disease with many unknowns, the simpler question may be, what do we know? From a histologic perspective, the initial swelling in lipedema is a result of both adipocyte hypertrophy and hyperplasia.¹⁰ In addi-

Table 2. Diagnostic Criteria of Lipedema

Almost exclusive occurrence in women
Bilateral and symmetrical manifestation with minimal involvement of the feet
Minimal pitting edema
Negative Kaposi–Stemmer sign
Pain, tenderness on pressure
Easy bruising
Persistent enlargement after elevation of the extremities or weight loss
Arms are affected 30% of the time*
Hypothermia of the skin*
Swelling worsens with orthostasis in summer*
Unaffected by caloric restriction*
Telangiectasias*

*Added by Herbst.³

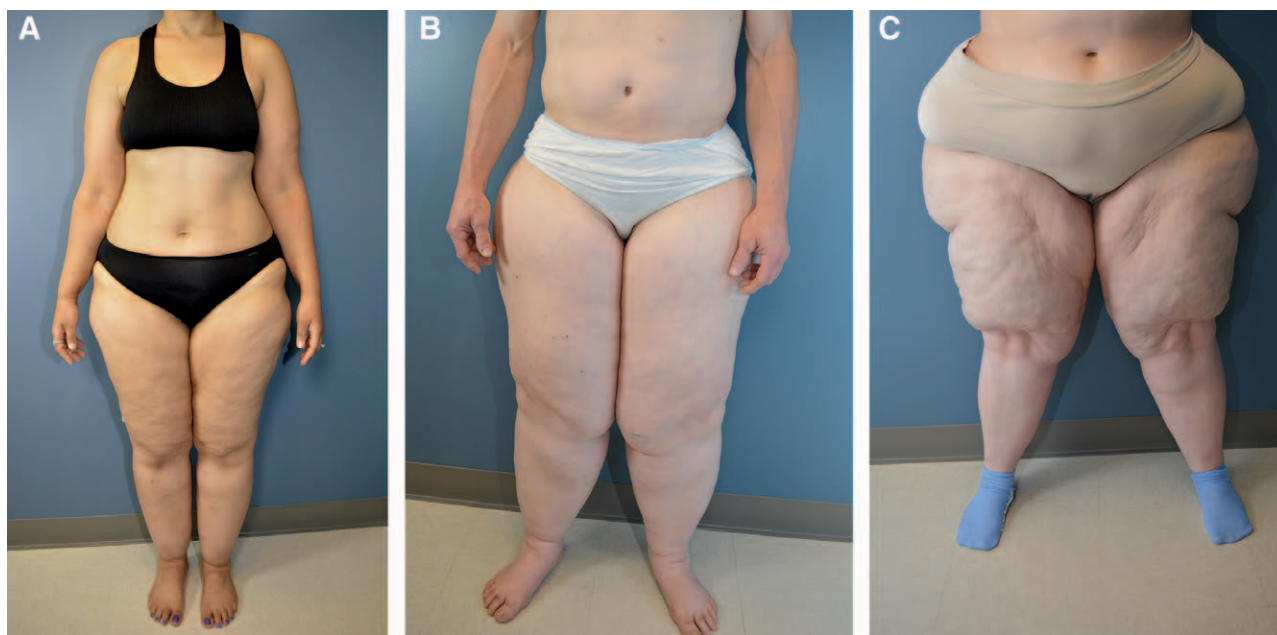


Fig. 1. Three patients who highlight common clinical findings associated with lipedema. A, A 52-year-old woman with type 3/4 lipedema, stage 2. B, A 51-year-old woman with type 3 lipedema, stage 2/3. Note the profound discrepancy between the patient's upper trunk and extremity adiposity. C, A 37-year-old woman with type 1/2 lipedema, stage 3.

tion to enlarged adipocytes, there is thickening of the interstitium with the presence of increased interstitial fluid, secondary to elevated hydrostatic pressure.¹¹⁻¹³ Although interstitial fluid is increased, at least in early stages, the lymphatic system seems to be functioning normally.¹⁴ Thus, the “edema” from lipedema at this stage is likely secondary to overwhelming the lymphatic pump, rather than a true dysfunction within the lymphatics themselves. However, as lipedema progresses, the lymphatic channels begin to stretch and dilate with development of many “microaneurysms” that have a tendency to leak. These leaking microaneurysms combine with the increased interstitial fluid to result in late-stage lipolymphedema.¹⁴⁻¹⁸

In addition to adipocyte hypertrophy, interstitial thickening, and lymphatic changes, the subdermal vascular plexus also undergoes conformational changes consistent with a microangiopathy. This microangiopathy results in capillary fragility, and leakage, which corresponds to the easy bruising and telangiectasias seen in lipedema patients.^{19,20} There also appears to be an influx of inflammatory cells within the interstitium, which may contribute to the signaling mechanisms involved with adipocyte hypertrophy.³

Table 3. Types of Lipedema

Type 1: Pelvis, buttocks, and hips
Type 2: Buttocks to knees, with formation of folds of fat around the inner side of the knee
Type 3: Buttocks to ankles
Type 4: Arms
Type 5: Isolated lower leg

LIPEDEMA MANAGEMENT

Because of its relatively unknown status in the medical community, there is a paucity of conclusive, supportive data regarding effective treatments of this disease. Based on the link between lymphatic dysfunction and adipocyte hypertrophy, and the progression to lipolymphedema in late stages of disease, it is therefore not surprising that treatments aimed at supporting lymphatic flow are useful adjuncts in managing lipedema; this includes complete decongestive therapy (which combines compression garments, manual lymphatic drainage, movement therapy, dietary recommendations, and skin care) and the use of home sequential pneumatic compression devices (eg, Flexitouch System; Tactile Medical, Minneapolis, Minn.; or Lymphapress Optimal; Lympha Press USA, Freehold, N.J.). Several literature reports have demonstrated the improvements in edema, lymph drainage, and capillary fragility with these measures.³

Although lipedema fat is resistant to lifestyle modifications, there is evidence to support the positive effects of exercise, particularly aquatic therapy, and lifestyle change on lymphedema, lymph flow, and overall health.³ Patients with late-stage lipedema, or significant pain, are often sedentary because of immobility and also subsequently develop lifestyle-induced obesity. Lifestyle modifications in these patients will therefore treat their obesity; however, the lipedema fat will remain.

As a result of the lack of psychosocial support for women with lipedema, they often suffer from psychosocial disorders, including depression, anxiety, and eating disorders. Therefore, proper counseling and treatment of these conditions are important.³

Additional medical treatment options that have had reported success in treating lipedema, or lymphedema, include beta-adrenergic agonists, corticosteroids, diuretics, flavonoids, and selenium.³ It is recommended that the use of these options be considered and managed by someone who regularly prescribes them, the patient's primary care physician who can monitor them regularly, or a physician who is knowledgeable about lipedema and lymphedema.

From a surgical perspective, the least invasive means of removing the painful fat of lipedema is through the use of suction lipectomy. It is important to note, however, that the techniques employed for lipectomy of lipedema fat are different from the techniques used for cosmetic liposuction.²¹⁻²⁵ Specifically, the techniques employed for lipedema liposuction utilize devices that remove fat in a gentler manner, such as the vibrating cannula associated with power-assisted liposuction or water-assisted liposuction. Reports have indicated that these methods may damage less lymphatic tissue than traditional techniques and therefore result in "lymphatic-sparing" adipose removal.²² Likewise, most surgeons treating lipedema with liposuction utilize specialized cannulas and orient the cannulas longitudinally within the lipedema subcutaneous adipose tissue to minimize potential injury to lymphatics. In addition, the volume of wetting solution used in these patients is often much less than that used in traditional liposuction. Although the literature on lipedema treatment is limited, there are several promising reports, largely from Germany and Europe, detailing the effectiveness of liposuction for the treatment of lipedema. Stutz and Krahl,²² Rapprich et al,^{23,24} and Schmeller et al²⁵ have published extensive reports on the utility of their specialized liposuction techniques in not only reducing the volume of lipedema fat but also slowing progression of disease, reducing lipedema pain, reducing altered gait and loss of mobility, and improving quality of life in these patients. Likewise, in my own series of patients, I have seen similar improvements in patient's mobility and ability to exercise without pain and to sit or stand for long periods of time without tenderness or heaviness.

The use of defined liposuction techniques and specialized pre- and postsurgical protocols in this patient population cannot be overstated, as the techniques are specifically utilized to minimize the risk of developing postoperative lymphedema.²² This is especially true in patients with late-stage lipedema who already have some clinical evidence of lymphatic compromise. In preparation for surgery, and postoperatively, it is also important to continue with lymphatic support measures, such as compression and complete decongestive therapy. These adjunctive treatments help prime the lymphatics for drainage of any postoperative edema and residual tumescent fluid utilized during the lipectomy procedure. Likewise, it is also important that patients continue with healthy lifestyle choices, including good eating habits and exercise. Although these lifestyle measures will not necessarily affect the lipedema fat, per se, they will improve the patients overall health and wellness before and after the procedures.

One of the greatest difficulties with treatment of lipedema is insurance coverage for the surgical treatment. Unfortunately, the combination of misconceptions about obesity and lipedema, along with the use of a code for suction lipectomy, which is often employed for cosmetic indications, has resulted in almost universal insurance denials. Hopefully, with increased awareness about this common disease, and also a greater understanding for the reconstructive nature of suction lipectomy techniques employed for removing lipedema subcutaneous adipose tissue, the women who suffer from lipedema will be able to receive treatment without the personal financial burden that currently exists.

CONCLUSIONS

Lipedema represents a common medical condition with many misconceptions. It is rarely taught in medical school and/or residency training, and as a result of this educational gap, a large population of patients suffering from this condition are forced to endure a plethora of unnecessary consultations, laboratory and radiological studies, and the psychosocial distress of being told it is their fault. With an incidence that may affect nearly 1 in 9 adult women, it is important to generate appropriate awareness, conduct additional research, and identify better diagnostic and treatment modalities so these women can obtain the care that they need and deserve.

Donald W. Buck II, MD

Plastic and Reconstructive Surgery
Washington University School of Medicine
Washington University Surgical Group
11155 Dunn Road, Suite 202N
St. Louis, MO 63136
E-mail: buckd@wudosis.wustl.edu

REFERENCES

- Allen EV, Hines EAJ. Lipedema of the legs: a syndrome characterized by fat legs and orthostatic edema. *Proc Staff Meet Mayo Clin.* 1940;15:184-187.
- Foldi E, and Foldi M. Lipedema. In: Foldi M, Foldi E, eds. *Foldi's Textbook of Lymphology*. Munich, Germany: Elsevier GmbH; 2006:417-427.
- Herbst KL. Rare adipose disorders (RADs) masquerading as obesity. *Acta Pharmacol Sin.* 2012;33:155-172.
- Wold LE, Hines EA, Jr, Allen EV. Lipedema of the legs: a syndrome characterized by fat legs and edema. *Ann Intern Med.* 1951;34:1243-1250.
- <http://www.lipoedema.co.uk>. Accessed on July 13, 2015.
- Herpertz U. Krankheitsspektrum des Lipödems an einer Lymphologischen Fachklinik - Erscheinungsformen, Mischbilder und Behandlungsmöglichkeiten. *Vasomed* 1997;6:301-307.
- Meier-Vollrath I, Schneider W, and Schmeller W. Lipödem: Verbesserte Lebensqualität durch Therapiekombination. *Dtsch Ärzteblatt* 2005;102:A1061-A1067.
- Rasmussen JC, Herbst KL, Aldrich MB, et al. An abnormal lymphatic phenotype is associated with subcutaneous adipose tissue deposits in Dercum's disease. *Obesity (Silver Spring)* 2014;22:2186-2192.
- Pascucci A, Lynch PJ. Lipedema with multiple lipomas. *Dermatol Online J.* 2010;16:4.
- van Geest AJ, Esten SCAM, Cambier, J-PRA, et al. Lymphatic disturbances in lipoedema. *Phlebologie* 2003;32:138-142.

11. Stallworth JM, Hennigar GR, Jonsson HT, Jr, et al. The chronically swollen painful extremity. A detailed study for possible etiological factors. *JAMA* 1974;228:1656–1659.
12. Greer KE. Lipedema of the legs. *Cutis* 1974;14:98.
13. Harwood CA, Bull RH, Evans J, et al. Lymphatic and venous function in lipoedema. *Br J Dermatol*. 1996;134:1–6.
14. Amann-Vesti BR, Franzeck UK, Bollinger A. Microlymphatic aneurysms in patients with lipedema. *Lymphology* 2001;34:170–175.
15. Partsch H, Stöberl C, Urbanek A, et al. Clinical use of indirect lymphography in different forms of leg edema. *Lymphology* 1988;21:152–160.
16. Tiedjen KU, Schultz-Ehrenburg U. Isotopenlymphographische Befunde beim Lipödem. In: Holzmann H, Altmeyer P, Hör G, eds. *Dermatologie und Nuklearmedizin*. Berlin: Springer-Verlag; 1985:432–438.
17. Bräutigam P, Földi E, Schaiper I, et al. Analysis of lymphatic drainage in various forms of leg edema using two compartment lymphoscintigraphy. *Lymphology* 1998;31:43–55.
18. Bilancini S, Lucchi M, Tucci S, et al. Functional lymphatic alterations in patients suffering from lipedema. *Angiology* 1995;46:333–339.
19. Curri SB, Merlen JF. [Microvascular disorders of adipose tissue]. *J Mal Vasc*. 1986;11:303–309.
20. Merlen JF, Curri SB, Sarteel AM. [Cellulitis, a conjunctive microvascular disease]. *Phlebologie* 1979;32:279–282.
21. Schmeller W, Meier-Vollrath I. Tumescent liposuction: a new and successful therapy for lipedema. *J Cutan Med Surg*. 2006;10:7–10.
22. Stutz JJ, Krahl D. Water jet-assisted liposuction for patients with lipoedema: histologic and immunohistologic analysis of the aspirates of 30 lipoedema patients. *Aesthetic Plast Surg*. 2009;33:153–162.
23. Rapprich S, Dingler A, Podda M. Liposuction is an effective treatment for lipedema—results of a study with 25 patients. *J Dtsch Dermatol Ges*. 2011;9:33–40.
24. Rapprich S, Baum S, Kaak I, et al. Treatment of lipoedema using liposuction. Results of our own surveys. *Phlebologie* 2015;3:1–13.
25. Schmeller W, Hueppe M, Meier-Vollrath I. Tumescent liposuction in lipoedema yields good long-term results. *Br J Dermatol*. 2012;166:161–168.